

*Marek Hartleb¹, Ewa Nowakowska-Duława¹, Magdalena Lesińska¹, Anna Kocłęga², Sławomira Kyrzcz-Krzemień², Jacek Pająk³, Jan Baron⁴

Primary hepatobiliary involvement in Hodgkin's disease – a case report

Pierwotna manifestacja wątrobowo-żółciowa choroby Hodgkina – opis przypadku

¹Department of Gastroenterology and Hepatology, Medical University of Silesia in Katowice
Head of Department: prof. Marek Hartleb, MD, PhD

²Department of Hematology and Bone Marrow Transplantation, Medical University of Silesia in Katowice
Head of Department: prof. Sławomira Kyrzcz-Krzemień, MD, PhD

³Department of Pathomorphology, Medical University of Silesia in Katowice
Head of Department: Maciej Kajor, MD, PhD

⁴Department of Radiology, Medical University of Silesia in Katowice
Head of Department: Jan Baron, MD, PhD

Summary

Hodgkin's lymphoma is usually a lymph node-based disease. Liver involvement is an unfavorable prognostic factor, as it generally occurs in late stage of this disease. We present a case of 48-year old patient, in whom Hodgkin's lymphoma started as cholestatic febrile disease with progressive liver failure. Cholestasis resulted from both the liver granulomatous hepatitis and stenosis of the hepatic biliary duct, imitating extrahepatic cholangiocarcinoma. The diagnosis of Hodgkin's disease was based on liver histology showing atypical lymphocytic cells and later confirmed by examination of axillary lymph node. Despite specific endoscopic and hematological treatment the patient died due to aggressive course of lymphoma and liver failure.

Key words: Hodgkin's lymphoma, liver involvement

Streszczenie

Chłoniak Hodgkina jest zwykle chorobą ograniczoną do węzłów chłonnych. Zajęcie wątroby jest niekorzystnym czynnikiem prognostycznym, ponieważ na ogół występuje dopiero w późnej fazie tej choroby. Przedstawiono przypadek 48-letniego pacjenta, u którego chłoniak Hodgkina rozpoczął się jako gorączkowa choroba cholestatyczna z postępującą niewydolnością wątroby. Przyczyną cholestazy było zarówno ziarniniakowe zapalenie wątroby, jak i zwężenie żółciowego przewodu wątrobowego, naśladującego raka dróg żółciowych. Rozpoznanie choroby Hodgkina opierało się na badaniu histopatologicznym biopsji wątrobowego, w którym ujawniono obecność nietypowych komórek limfoidalnych. Rozpoznanie to zostało potwierdzone w badaniu histopatologicznym pachowego węzła chłonnego. Mimo zastosowania leczenia endoskopowego i hematologicznego pacjent zmarł z powodu szybkiego postępu chłoniaka i niewydolności wątroby.

Słowa kluczowe: chłoniak Hodgkina, dysfunkcja wątroby

INTRODUCTION

In general, Hodgkin's disease is a lymph node-based disease, which usually spreads along the lymphatic chain to contiguous lymph node areas. Liver involvement in Hodgkin's disease depends on its stage – it is rare in early phase and common in end-stage of this disease. Consequently, less than 4% of patients with newly identified Hodgkin's disease have significant hepatic symptoms (1). The liver was infiltrated with atypi-

cal lymphoid cells in 5-10% of cases in biopsy studies and in up to 50% of cases at autopsies (2, 3). Only occasionally the initial clinical presentation of Hodgkin's disease comes from the liver. In such cases this hematological disease may imitate the primary liver or biliary tract disease. We present an unusual case of Hodgkin's disease that started as cholestatic hepatopathy caused by both the granulomatous hepatitis and the stenosis of extrahepatic biliary duct.

CASE DESCRIPTION

A 48-year old man was admitted to local hospital because of cholestasis, loss of weight (20 kg over 6 months), night sweats and fever (March, 2011). He denied any abdominal pain. Four years earlier he underwent surgery due to perforation of small bowel and peritonitis secondary to blunt abdominal trauma. There was no history of viral hepatitis and he was not taking any medication. The patient was a farmer specialized in fruit growing. Each day he was smoking approximately 20 cigarettes and was drinking 3 cups of coffee.

An abdominal ultrasonography showed hepatosplenomegaly (the longitudinal span of the right hepatic lobe was 15 cm and that of spleen 13 cm). In the right hepatic lobe tumor-like lesions with the greatest diameter of 4 cm were visualized.

An abdominal computed tomography (CT) scan demonstrated enlarged and heterogenous liver with disseminated hypovascular focal lesions located in the segments 2, 5, 6 and 8. The spleen was enlarged and contained solid focal lesions suggestive of metastases (fig. 1). Besides, CT demonstrated multiple retroperitoneal and hepatic perihilar lymph nodes 10-13 mm in size. The pancreas was of normal size without focal lesions. An endoscopic retrograde cholangiopancreatography (ERCP) showed stenosis of the hepatic biliary duct at the level of the cystic duct. The intrahepatic biliary ducts were moderately dilated. The plastic stent 10 F 12 cm was inserted through the stenosis. It resulted in a decrease of serum bilirubin level from 4.5 to 0.8 mg/dl.

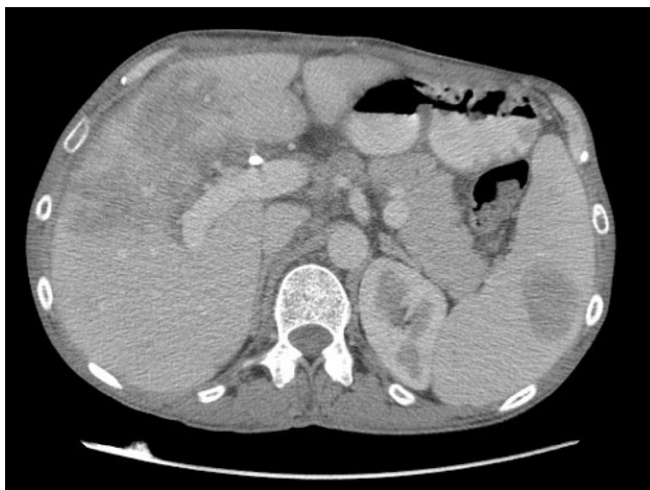

Fig. 1. Abdominal CT in portal venous phase shows hepatosplenomegaly with markedly heterogenous perfusion of the liver and large focal lesion within the spleen.

The liver biopsy showed features of granulomatous hepatitis with no evidence of malignant disease (April, 2011). The patient was referred to our department with strong suspicion of cholangiocarcinoma (July, 2011). The physical examination confirmed hepatosplenomegaly and disclosed mild bilateral enlarge-

ment of axillary (size 1-1.5 cm) and inguinal (size 1 cm) lymph nodes. The patient was febrile and used antipyretics. The administration of corticosteroids (prednisone 40 mg) justified by hepatic histology stopped the fever immediately. Relevant laboratory findings included: total bilirubin 3.2 mg/dl, alkaline phosphatase; ALP 622 IU/l (upper reference value 120 IU/l), gamma-glutamyltranspeptidase; GGTP 646 IU/l (upper reference value 55 IU/l), alanine aminotransferases; ALT 118 IU/l (upper reference value 45 IU/l), aspartate aminotransferases; AST 86 IU/l (upper reference value 35 IU/l) and C-reactive protein; CRP 74.6 mg/l (upper reference value 5 mg/l). Serological examinations for hepatitis A virus, hepatitis B virus, hepatitis C virus, human immunodeficiency virus and Epstein-Barr virus were negative. Tests for HCV RNA, antinuclear antibodies, antimitochondrial antibodies and anti-smooth muscle antibodies were also negative. The serum level of CA19-9 was 71.8 IU/l (upper reference value 39 IU/l). The Quantiferon test was negative.

During hospital follow-up the left-side anisocoria has occurred. For this reason the computed tomography of the brain and the chest radiography were performed. These examinations did not reveal any significant pathology.

Subsequently, the patient underwent second percutaneous liver biopsy that was examined by pathomorphologist experienced in diagnostics of lymphomas. The core including 12 portal areas was available for histological examination. The lobular architecture was preserved. The hepatocytes were swollen and showed features of canalicular and cytoplasmic cholestasis. Most of the portal tracts contained a mixed inflammatory infiltrate predominantly composed of lymphocytes. The infiltrate was mostly composed of T cells (CD3+, CD2+), although focally B cells (CD20+, CD79a+) were also seen. No eosinophils were identified. Several granulomas were found within the hepatic lobules. The granulomas were composed of histiocytic cells showing no signs of necrosis or polynuclearity and large lymphocytes showing 'atypical' nuclear features, such as angulated and enlarged nuclei and detectable small nucleoli. Immunohistochemical studies showed following immunophenotype of the atypical cells: CD30 (+), PAX5 (+), CD3 (-), CD2 (-), Alk-1 (-), CD20 (-), EMA (-), CD79a inconclusive and CD15 (-). Despite absence of classical Reed-Sternberg cells the diagnosis of Hodgkin's disease has been proposed (fig. 2 A and B).

Consequently, the patient was transferred to hematological department for further diagnosis and specific treatment (August, 2011). On admission the hemoglobin level was 13.3 g/dl, the white blood cells count was 9.76 G/l and platelets count was 223 G/l. Among liver function tests the serum level of ALT was 107 IU/l, AST was 67 IU/l, ALP was 497 IU/l, GGTP was 459 IU/l and LDH was 285 IU/l (upper reference value 180 IU/l). The serum albumin level was 2.9 g/dl (reference range 3.5-5.0 g/dl) and serum IgG level was 4.2 g/l (reference range 7-16 g/l).

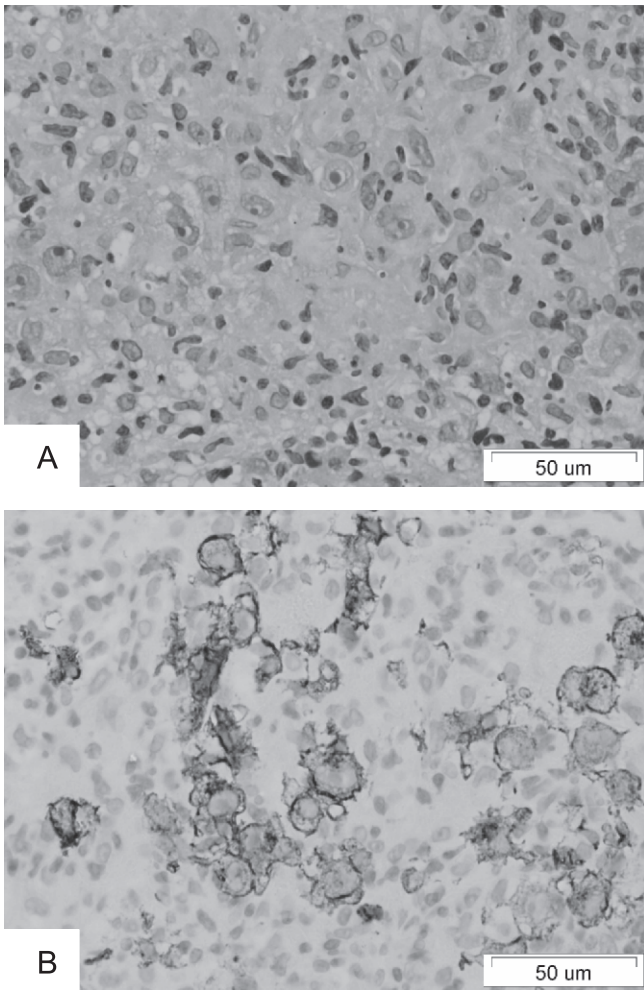


Fig. 2. Histology from the liver biopsy, stain H-E, 400x. Liver granuloma composed of large, atypical mononuclear cells of Hodgkin's type (A). These cells stain positive for CD30 (B).

The trepanobiopsy was performed and on histopathology the bone marrow occupied about 50% of intertrabecular bone spaces. Fibrosis was absent and Hodgkin's infiltrates were not found. Immunostaining for CD30 positive cells was negative. Iron staining was positive. The blast cells expressing CD34+ contributed to less than 1% of all cells. Normal growing of all cell lines was preserved. Given the near normal image of bone marrow the axillary lymph node was resected for histopathological examination. **This examination was consistent with the lymphocytic depletion classical Hodgkin's lymphoma** (fig. 3).

The patient was re-hospitalized to initiate the cytoreductive treatment (October, 2011). At admission the patient's clinical state was severe. He complained at general lassitude and on physical examination presented massive peripheral edema, hepatosplenomegaly and diminished alveolar murmur over the right lung. Laboratory blood examination included hemoglobin level of 9.5 g/dl with normal count of platelets and white blood cells. The patient was jaundiced and his serum bilirubin level was 5.79 mg/dl. The total protein and albumin levels were 4.9 g/dl and 1.2 g/dl, respectively. The serum

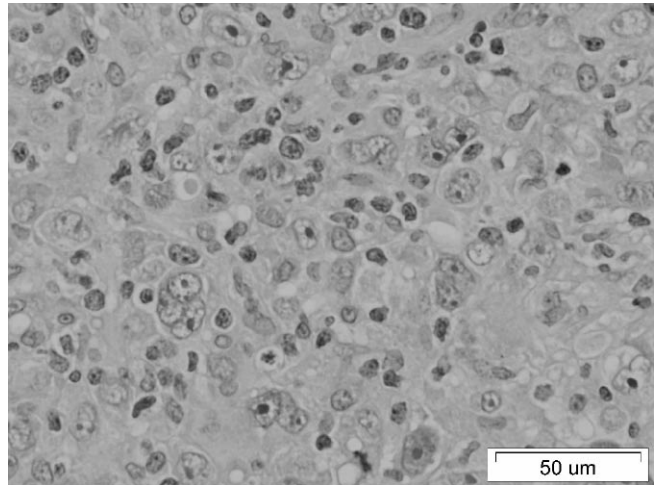


Fig. 3. Histology of resected axillary lymph node, stain H-E, 400x. Many mononuclear cells of Hodgkin's type and single Reed-Sternberg cells.

level of beta2-microglobulin was 7735 mg/l (reference range 1500-3000 mg/l) and serum CRP was 129 mg/l.

Chest CT showed large amount of fluid in the right pleural cavity (thickness of 5 cm), while the left pleural cavity was intact. The parenchymal alveolitis-type lesions (ill-defined confluent opacities creating an image of "frosted glass") were described in many areas of the right lung and in the basal part of the left lung. Two small lymph nodes have been visualized in the branching of right pulmonary artery. Besides, lymph nodes with diameter of 6-8 mm were found along the pericardium, in the axillary fosses and in subclavicular region. In the mediastinum no enlarged lymph nodes were found.

The chemotherapy according to BEACOPP schedule was begun (Etoposide 160 mg iv. on days 1-3, Doxorubicin 40 mg iv. on day 1, Cyclophosphamide 1000 mg iv. on day 1, Procarbazine 150 mg *peroral* on days 1-7, Bleomycin 15 mg iv. on day 8, Vincristine 2 mg iv. on day 8, Prednisone 60 mg *peroral* on days 1-13). The decision to implement this treatment regimen was made after taking into account the young age of the patient and very aggressive nature of the disease. The lymphoma was characterized by high mitotic index (about 80% Ki67-positive cells), and was classified as IVB according to Ann-Arbor system (disseminated lymphoma occurring on both sides of the diaphragm with involvement of extra lymphatic organs and presence of general symptoms). Moreover, in the reported patient the Hodgkin's lymphoma presented high International Prognostic Score (IPS = 5), a score designed for advanced forms of this disease, based on evaluation of several parameters including the age, sex, Ann-Arbor classification and serum albumin level. Starting from the 9th day, the course of chemotherapy was complicated by agranulocytosis and bacteriemia (ESBL-positive *Klebsiella pneumoniae*). Recombinant human granulocyte colony-stimulating factor (G-CSF) was administered subcutaneously at dose 300 mg/24 h. Despite wide-spectrum antibiotics and supportive ther-

apy the patient developed respiratory failure requiring use of mechanical ventilation. On 13th day of hospitalization the patient was transferred to Intensive Care Unit, where he died because of cardio-respiratory insufficiency.

DISCUSSION

The clinical and biochemical features of liver injury were those of a cholestatic hepatitis. Liver involvement in Hodgkin's disease is characterized by significant elevation of alkaline phosphatase, while aminotransferase levels are only moderately increased or normal. The liver size is usually increased and jaundice appears in 3-8% of patients (2, 4). The liver involvement in Hodgkin's disease rarely pose a clinical problem, however, it may complicate therapeutic decisions due to impaired drug metabolism caused by interrupted hepatic bile flow. In rare cases the massive infiltration of the liver by neoplastic cells is a cause of acute liver failure.

The cholestasis in Hodgkin's disease may result from many pathologies involving intrahepatic or extrahepatic biliary ducts as well as hepatic bile production. More specifically, the cholestasis in patients with Hodgkin's disease may be secondary to ductal injury and ductopenia, bland cholestasis with no liver injury, infiltration by lymphoma cells, extrahepatic biliary tumor deposition or compression of the extrahepatic biliary ducts by enlarged lymph nodes. In rare cases the jaundice is caused by hemolysis (5).

Most commonly the liver biopsy shows infiltration of portal triads with atypical lymphoid cells, eosinophils and plasmacytes. Reed-Sternberg cells typical for Hodgkin's disease are rarely seen. Occasionally no stigmata of Hodgkin's disease are found and non-specific cholestatic hepatitis is concluding histopathologic diagnosis. In our case the presence of 'atypical' lymphoid cells was considered suggestive of Hodgkin's disease, even in the absence of Reed-Sternberg cells (6). This diagnosis was unequivocally confirmed by histopathological examination of the peripheral lymph node. In several previous studies percutaneous

liver biopsies missed infiltrates indicative of Hodgkin's disease, which was discovered in open wedge biopsies or in autopsies (2, 7). In our patient the second liver biopsy disclosed Hodgkin cells. On two consecutive liver biopsies the histopathological image was dominated by granulomatous hepatitis. Non-caseating granulomas were occasionally found in the liver involved by Hodgkin or non-Hodgkin-lymphomas (8). Granulomas developing in portal areas may injure interlobular biliary ducts (8). The circumstances predisposing to development of granulomas in Hodgkin's disease are not known.

Jaundice developing during follow-up is common finding in end-stage Hodgkin's lymphoma (4), however, cholestatic jaundice as an initial presentation of this disease is a rare phenomenon. Liangpunsakul et al. (2) found in the literature 25 such patients till 1996. Since then we found another 5 new cases, among them 2 presenting with acute liver failure (9-13). Due to rarity of primary liver presentation almost all reported cases were perceived to represent various forms of primary liver disease, such like drug-induced cholestasis, seronegative autoimmune hepatitis or obstructive cholangitis. Patients in whom Hodgkin's disease presented as primary hepatopathy showed enlarged liver, cholestasis and fever as initial clinical symptoms, whereas lymphadenopathy was usually not noticeable in the lymph nodal groups accessible to palpation. High aminotransferase activity was found in minority of patients (14). Some authors suggested that liver may be the primary site of development of Hodgkin's lymphoma, similarly as it occurs in non-Hodgkin variants (12). Narrowing of the common bile duct caused by infiltration by Hodgkin's disease with dilatation of the left hepatic duct was reported only in a single patient (15). Our patient is, therefore, the second published case of Hodgkin's disease with extrahepatic biliary stricture imitating cholangiocarcinoma.

In summary, we presented a case of Hodgkin's disease with primary hepatobiliary manifestation under the form of granulomatous hepatitis and stricture of the hepatic bile duct imitating cholangiocarcinoma.

BIBLIOGRAPHY

1. Cello JP, Grendell JH: The liver in systemic conditions. [In:] Zakim D, Boyer TD (editors). *Hepatology, a Textbook of Liver Disease*. Philadelphia, Saunders 1990; pp. 1423-1425.
2. Liangpunsakul S, Paul Kwo P, Koukoulis GK: Hodgkin's disease presenting as cholestatic hepatitis with prominent ductal injury. *Eur J Gastroenterol Hepatol* 2002; 14: 323-327.
3. Skovsgaard T, Brinckmeyer LM, Vesterager L et al.: The liver in Hodgkin's disease-II. Histopathologic findings. *Eur J Cancer Clin Oncol* 1982; 18: 429-435.
4. Bouroncle BA, Old JW, Vasquez AG: Pathogenesis of jaundice in Hodgkin's disease. *Arch Intern Med* 1962; 110: 872-883.
5. Birrer MJ, Young RC: Differential diagnosis of jaundice in lymphoma patients. *Semin Liver Dis* 1987; 7: 269-277.
6. Dich NH, Goodman ZD, Klein MA: Hepatic involvement in Hodgkin's disease. *Cancer* 1989; 64: 2121-2126.
7. Bagley CM, Roth JA, Thomas LB et al.: Liver biopsy in Hodgkin's disease. Clinicopathologic correlations in 127 patients. *Ann Int Med* 1972; 76: 219-225.
8. Lagana SM, Moreira RK, Lefkowitz JH: Hepatic granulomas: pathogenesis and differential diagnosis. *Clin Liver Dis* 2010; 14: 605-617.
9. Ortín X, Rodríguez-Luaces M, Bosch R et al.: Acute liver failure as the first manifestation of very late relapsing of Hodgkin's disease. *Hematol Rep* 2010; 2: e5.
10. Yokomori H, Kaneko F, Sato A et al.: Primary hepatic presentation of Hodgkin's lymphoma: A case report. *Hepatol Res* 2008; 38: 1054-7. Epub 2008.
11. Vardareli E, Dündar E, Aslan V et al.: Acute liver failure due to Hodgkin's lymphoma. *Med Princ Pract* 2004; 13: 372-374.

12. Nohgawa M, Yonetani N, Sugiyama T: Hodgkin's disease presenting with progressive liver failure. *Rinsho Ketsueki* 2002; 43: 857-861.
13. Chim CS, Choy C, Ooi CG et al.: Hodgkin's disease with primary manifestation in the liver. *Leuk Lymphoma* 2000; 37: 629-632.
14. Cervantes F, Briones J, Bruguera M et al.: Hodgkin's disease presenting as a cholestatic febrile illness: incidence and main characteristics in a series of 421 patients. *Ann Hematol* 1996; 72: 357-360.
15. Martin KR, Moore TJ, Wright RA: Obstructive jaundice secondary to primary biliary involvement with Hodgkin's disease. *Am J Gastroenterol* 1992; 87: 1194-1195.

received/otrzymano: 20.06.2012

accepted/zaakceptowano: 18.07.2012

Address/adres:

*Marek Hartleb

Department of Gastroenterology and Hepatology

Medical University of Silesia

ul. Medyków 14, 40-752 Katowice

tel.: +48 (32) 789-44-02

e-mail: mhartleb@sum.edu.pl